

Erratum

Minimally Invasive Cardiac Surgery for Resection of Right Atrial Hepatic Tumor in an Octogenarian

[*Chin Med J (Taipei)* 2002;65:345-347]

Tsung-Po Tsai, Jung-Min Yu

Department of Cardiothoracic Surgery, Chung Shan Medical University Hospital; and Chung Shan Medical University School of Medicine, Taichung, Taiwan, R.O.C.

The Publisher regrets that the Figure 3 on page 832 of the above paper was incorrect and it is reprinted correctly here in entirety:

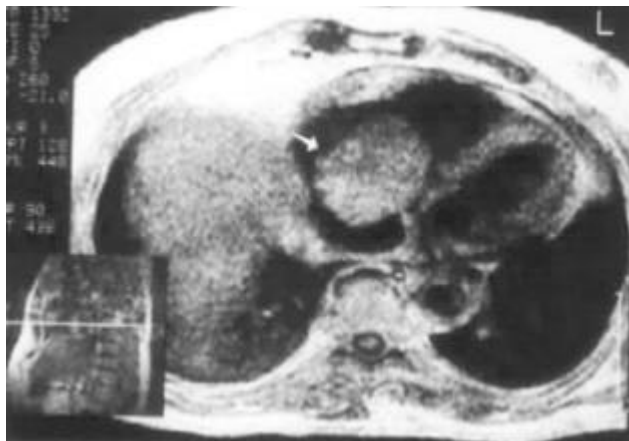


Fig. 3. MRI of thorax before atrial tumor resection.