

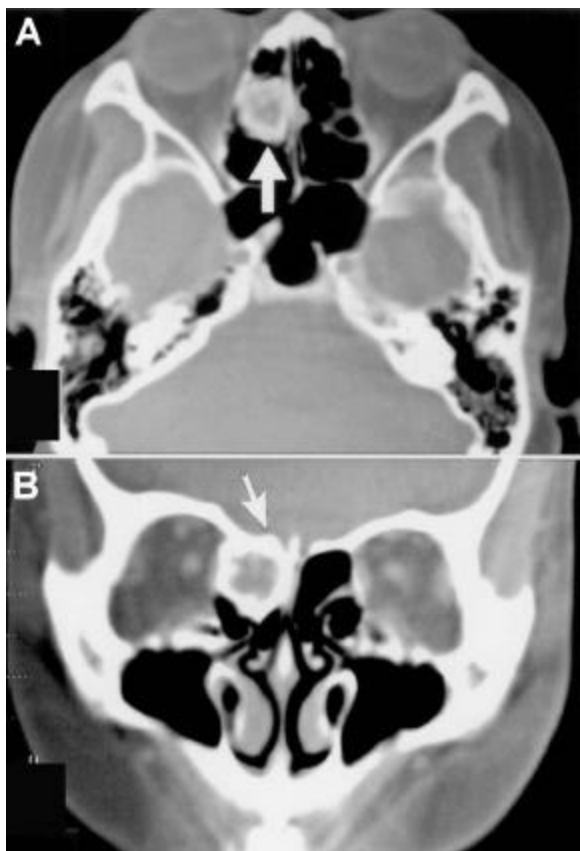
Erratum

Fibrous Dysplasia of the Ethmoid Sinus

Tung-Lung Tsai, Ching-Yin Ho, Yuan-Ching Guo, Winby Chen, Ching-Zong Lin

Departments of ¹Otolaryngology, ²Pathology, Taipei Veterans General Hospital; and National Yang-Ming University, Taipei, Taiwan.

An error was introduced into a Case Report by Tsai *et al.*, which appeared in the February issue of the Journal of the Chinese Medical Association (Fibrous Dysplasia of the Ethmoid Sinus. *J Chin Med Assoc* 2003;66:131-133). The photographs of Figures 1 and 2 were misplaced and the correct ones are shown as follows:



Figs. 1. Computed tomographic scans of the paranasal sinuses revealed a heterogeneous low-density lesion with some calcification spots in the right ethmoid sinus. (A: axial section, B: coronal section. Arrow).

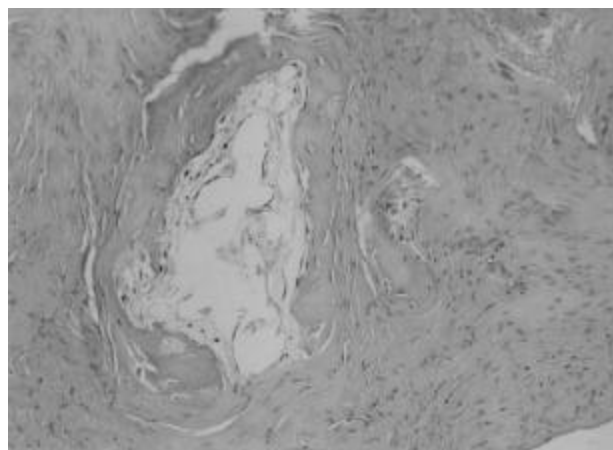


Fig. 2. The specimen showed haphazard woven bones embedded in fibrous tissue without osteoblastic rimming around the woven bone. (H&E stain, $\times 200$).

The publisher sincerely regrets any confusion caused by this error.