

# Assessment of Bilateral Inferior Petrosal Sinus Sampling (BIPSS) in the Diagnosis of Cushing's Disease

Liang-Yu Lin<sup>1</sup>, Michael Mu-Huo Teng<sup>2,4</sup>, Chun-I Huang<sup>3,4</sup>, Wen-Ya Ma<sup>5</sup>, Kang-Ling Wang<sup>6</sup>,  
Hong-Da Lin<sup>1,4</sup>, Justin G.S. Won<sup>1,4\*</sup>

<sup>1</sup>Division of Endocrinology and Metabolism, Department of Medicine, <sup>2</sup>Division of Neuroradiology, Department of Radiology, and <sup>3</sup>Department of Emergency Medicine, Taipei Veterans General Hospital, <sup>4</sup>National Yang-Ming University School of Medicine, Taipei, <sup>5</sup>Division of Endocrinology and Metabolism, Department of Internal Medicine, Tao-Yuan Veterans Hospital, and <sup>6</sup>Department of Medicine, Tao-Yuan Armed Forces General Hospital, Tao-Yuan, Taiwan, R.O.C.

**Background:** The differential diagnosis of adrenocorticotropin (ACTH)-dependent Cushing's syndrome (CS) remains a challenging issue for clinical endocrinologists. In this respect, bilateral inferior petrosal sinus sampling (BIPSS) appears to be the most sensitive and specific test. Here, we report our 15-year experience of analyzing the performance of BIPSS, both in the correct diagnosis and in the precise lateralization of tumors in patients with Cushing's disease (CD).

**Methods:** Between 1992 and 2006, 18 patients with CD (16 females, 2 males; age range, 14–56 years) were admitted to Taipei Veterans General Hospital and subjected to BIPSS plus ovine corticotropin-releasing hormone (oCRH) stimulation. Four of them had previously undergone transsphenoidal hypophysectomy (TSH) and had a recurrence thereafter. BIPSS was performed by inserting a catheter in the right and left inferior petrosal sinus for ACTH assay via a femoral vein puncture. An inferior petrosal sinus/peripheral ACTH ratio (C/P ratio)  $\geq 2$  at baseline or  $\geq 3$  after oCRH injection indicated a pituitary origin of ACTH secretion, and an interpetrosal ACTH gradient (IPS ratio)  $\geq 1.4$  at baseline or after oCRH indicated evidence of lateralization.

**Results:** Positive BIPSS results were found in 16 patients at baseline and in 17 patients after oCRH injection. In 17 out of 18 patients, TSH was subsequently carried out and a pituitary source was confirmed on histopathologic examination. The only 1 false-negative test result was noted in a patient who had undergone previous TSH. Thus, the sensitivities of BIPSS for the diagnosis of CD before and after oCRH stimulation were 89% and 94%, respectively. Moreover, using an IPS ratio  $\geq 1.4$  as a criterion, BIPSS correctly lateralized the tumor in 9 of 17 and 10 of 17 patients at baseline and after oCRH stimulation, respectively, including in 2 patients who had a centrally located tumor and who had an IPS ratio  $< 1.4$ . Thus, the sensitivities of lateralization of BIPSS were 53% and 59%, respectively. None of the 4 patients who had previous TSH were precisely localized by BIPSS. If these 4 patients were excluded, the sensitivities of BIPSS for localizing in the patients who had not undergone previous operation increased to 70% (9/13) at baseline and 77% (10/13) after oCRH stimulation, respectively.

**Conclusion:** BIPSS combined with oCRH stimulation is a safe and reliable examination both in the differential diagnosis of CD and in the correct lateralization of pituitary microadenoma in patients without previous pituitary surgery. Nevertheless, this procedure may provide misleading results in patients who have received previous pituitary surgery. [*J Chin Med Assoc* 2007;70(1):4–10]

**Key Words:** corticotropin-releasing hormone, Cushing's disease, inferior petrosal sinus sampling

## Introduction

The differential diagnosis of adrenocorticotropin (ACTH)-dependent Cushing's syndrome (CS), that

is, discrimination between pituitary-dependent and ectopic CS, remains a challenging issue for clinical endocrinologists. These 2 disease entities may be indistinguishable clinically, and their plasma ACTH levels are

\*Correspondence to: Dr Justin G.S. Won, Division of Endocrinology and Metabolism, Department of Medicine, Taipei Veterans General Hospital, 201, Section 2, Shih-Pai Road, Taipei 112, Taiwan, R.O.C.  
E-mail: gswon@vghtpe.gov.tw • Received: June 8, 2006 • Accepted: November 17, 2006

often similar. In addition, because of the small size of these pituitary tumors, 40–50% are not localized preoperatively even by sophisticated magnetic resonance imaging (MRI).<sup>1</sup> Although some noninvasive tests such as the high-dose dexamethasone suppression test (HDDST) and the ovine corticotropin-releasing hormone (oCRH) stimulation test are widely used for this purpose, the most convincing method has been the bilateral inferior sinus sampling (BIPSS) procedure, in which a diagnostic accuracy of near 100% has been reported, especially when combined with oCRH stimulation.<sup>2,3</sup>

BIPSS, in addition to providing information about the precise source of ACTH-secreting pituitary microadenoma, also provides important information to enable a neurosurgeon to localize the pituitary tumor preoperatively.<sup>4,5</sup> A unilateral elevation of ACTH (a ratio of interpetrosal ACTH  $\geq 1.4$ ) suggests the existence of a laterality and indicates the presence of an ACTH-producing microadenoma in the ipsilateral side of the pituitary gland, which might allow the neurosurgeon to perform a hemiphysectomy rather than a total hypophysectomy in case the microadenoma is too small to identify.

In the present study, the performances of BIPSS combined with oCRH stimulation in the differential diagnosis of Cushing's disease (CD) and in the preoperative localization of pituitary microadenoma were determined. To our knowledge, this is the first investigation attempting to discover the utility of this procedure in patients with CD in Taiwan.

## Methods

### Patients

Between 1992 and 2006, 18 patients were admitted to Taipei Veterans General Hospital with CD (16 females, 2 males; age range, 14–56 years). They were subjected to BIPSS plus oCRH stimulation. Four patients (case no. 1, 2, 5, 6) had undergone transsphenoidal hypophysectomy (TSH) previously and had a recurrence. The diagnosis of CS was established by full-blown clinical manifestations, elevated 24-hour urinary free cortisol (UFC) levels, loss of circadian rhythm of serum cortisol, and non-suppressibility of serum cortisol or UFC to the low-dose dexamethasone suppression test (LDDST) (Table 1). Furthermore, most of the patients were

**Table 1.** Biochemical features of 18 patients with Cushing's disease

Patient no.	Sex	Age (yr)	Baseline				UFC ( $\mu\text{g}/\text{d}$ )*	LDDST <sup>†</sup>	HDDST <sup>†</sup>	oCRH stimulation test <sup>§</sup>
			Plasma ACTH (pg/mL)		Plasma cortisol (mg/dL)					
			8 AM	10 PM	8 AM	10 PM				
1	F	40	6.2	X	15.8	12.0	80.0	NS	NS	X
2	F	26	106.7	X	53.0	X	477.0	X	X	Y
3	F	53	50.0	68.4	24.7	18.3	74.6	NS	NS	Y
4	F	44	23.5	21.3	17.9	36.8	124.8	NS	S	Y
5	F	37	46.4	24.1	8.9	9.0	57.5	NS	S	Y
6	M	19	152.3	128.3	33.5	23.7	257.4	NS	NS	Y
7	M	14	63.0	75.0	13.4	28.4	787.0	NS	NS	Y
8	F	41	64.5	31.8	37.4	13.2	301.8	NS	S	Y
9	F	35	62.5	52.8	18.3	12.4	121.5	NS	S	Y
10	F	26	44.5	60.0	19.1	18.2	335.7	X	NS	N
11	F	36	131.0	107.3	48.0	33.2	1,069.5	X	X	N
12	F	33	59.5	73.3	21.7	23.8	666.7	X	S	Y
13	F	31	59.8	17.8	22.8	13.4	232.0	X	S	Y
14	F	36	20.5	18.8	7.4	14.5	469.1	X	S	N
15	F	55	138.0	102.5	20.5	11.4	259.5	X	S	Y
16	F	28	53.0	87.0	21.9	20.6	473.0	X	S	Y
17	F	49	40.8	34.8	21.2	12.2	147.0	X	S	N
18	F	43	69.8	49.8	26.6	26.1	359.9	NS	S	N

\*UFC=urinary free cortisol, normal <100  $\mu\text{g}/\text{day}$ ; <sup>†</sup>LDDST=low-dose dexamethasone suppression test, dexamethasone 0.5 mg per oral q6h for 2 days; <sup>‡</sup>HDDST=high-dose dexamethasone suppression test, dexamethasone 2 mg per oral q6h for 2 days; <sup>§</sup>oCRH stimulation test=intravenous bolus of ovine corticotropin-releasing hormone 100  $\mu\text{g}$  at 8 AM. ACTH=adrenocorticotropin; X=not done; NS=nonsuppressible; Y=positive response defined as an increment  $\geq 20\%$  of serum cortisol over baseline or  $\geq 50\%$  or more of plasma ACTH over baseline; S=suppressible, 8 AM cortisol <50% of baseline on day 3 or UFC <10% of baseline on day 2; N=negative response.

also subjected to the HDDST and oCRH stimulation tests in order to distinguish CD from adrenal or ectopic CS.

Imaging studies including high-resolution contrast-enhanced thin-section computed tomography (CT) and MRI were obtained in each patient before BIPSS and were read by 2 independent neuroradiologists. A pituitary tumor was revealed in 14 patients. In patient no. 17, 2 distinct microadenomas were disclosed on both sides of the pituitary. No discrete lesion was found in the remaining 3 subjects. In our study, the operative findings of the surgeon were used as the reference standard for lateralization of the pituitary tumor, except in patient no. 10, who was unsuitable for surgery due to poor pneumatization of the sphenoid sinus (conchal sella).

### **BIPSS**

The procedures were performed as described by Oldfield et al.<sup>6</sup> In brief, a catheter was placed in the orifice of each of the right and left inferior petrosal sinuses via a femoral vein approach. Blood samples for ACTH assay were obtained simultaneously from both sides of the inferior petrosal sinus and from a peripheral vein before and 3, 5 and 10 minutes after oCRH 100 µg was given as a bolus injection. Synthetic oCRH was purchased from Bachem (Torrance, CA, USA) and was reconstituted by dissolving oCRH powder in distilled water and sterilizing through a 0.22 µm Millipore filter. Blood samples were collected in chilled test tubes containing sodium ethylenediamine tetraacetic acid (EDTA), centrifuged at 4°C, and the plasma was stored at -20°C until ACTH levels were determined by immunoradiometric assay (IRMA). ACTH concentrations in the bilateral sampling and in the periphery were calculated for C/P ratio for each set of samples. A C/P ratio  $\geq 2$  at baseline or  $\geq 3$  after oCRH injection was considered to indicate a pituitary origin of ACTH secretion. Then, the ACTH concentration ratio between the right and left inferior petrosal sinuses (IPS ratio) was calculated. A ratio  $\geq 1.4$  either before or after oCRH injection was considered to be evidence of lateralization of ACTH secretion and indicative of a tumor on the ipsilateral side of the pituitary gland.

### **Hormone assays**

Plasma ACTH levels were determined by IRMA (Nichols Institute, San Juan Capistrano, CA, USA). The intra- and interassay coefficients of variation were 3.0% and 7.8%, respectively. The minimal detected concentration was 1 pg/mL, and the reference range in the morning was 9–52 pg/mL. Serum cortisol was

measured by a homemade radioimmunoassay (RIA), using an antiserum raised in rabbit (Ig G-F-1, Ig G 1:100 dilution; Ig G Corporation, Nashville, TN, USA) and a tracer from Amersham Biosciences (cortisol-3-(*O*-carboxymethyl) oximino-(2-[<sup>125</sup>I] iodohistamine), IM129, Buckinghamshire, UK). The intra- and interassay coefficients of variation were 4.1% and 10.2%, respectively. The minimal detectable cortisol level was 0.02 µg/dL. A 1:20 dilution was created by adding 50 µL serum to 1,950 µL buffer solution before RIA was performed. UFC levels were determined by RIA as described above after extraction by dichloromethane. The intra- and interassay coefficients of variation were 6.2% and <10%, respectively. The normal reference value was <100 µg/day in our laboratory.

## **Results**

### **Diagnosis of ACTH-dependent CS**

The detailed biochemical features of the 18 patients with CD are shown in Table 1. All patients had midnight cortisol levels that were both >7.5 µg/dL and >50% of the corresponding morning cortisol concentrations, suggesting a loss of circadian rhythm of cortisol secretion. Increased 24-hour UFC excretion (>100 µg/day) was found in 15 of the 18 patients (83%). Nine subjects, including 3 patients who had normal 24-hour UFC excretion, underwent standard LDDST, and all showed a nonsuppressible serum cortisol concentration and UFC excretion, thus confirming the diagnosis of active CS. Except for patient no. 1 who had recurrent CD and ACTH level of 6.2 pg/mL, the plasma ACTH levels in all the other patients ranged from 20 to 152 pg/mL, consistent with the diagnosis of ACTH-dependent CS.

### **Results of noninvasive localization methods**

As shown in Table 1, using a criterion of suppression of  $\geq 50\%$  of serum cortisol level or suppression of  $\geq 90\%$  of UFC excretion, the sensitivity of HDDST was 69% (11/16). A similar sensitivity (71%; 12/17) was achieved by the oCRH test when a criterion of an increase of  $\geq 50\%$  of plasma ACTH concentration or an increase of  $\geq 20\%$  of serum cortisol level was used.

As shown in Table 2, imaging studies showed that 14 of the 18 patients had CT/MRI evidence suggesting pituitary tumors (78%), which appeared to have comparable sensitivity to the endocrine dynamic tests. However, correct lateralization was confirmed in 9 of 17 patients (52%) and in 6 of the 13 fresh cases (46%) after surgery. Three of the 4 patients who had recurrence were correctly lateralized (75%) by imaging studies.

**Table 2.** Imaging findings and results of bilateral inferior petrosal sinus sampling (BIPSS) in 18 patients with Cushing's disease

Patient no.	Imaging findings CT/MRI	BIPSS results—ACTH (pg/mL)							Operative findings	Therapeutic outcomes
		Baseline			C/P ratio		IPS ratio (side)			
		R	L	P	Basal	Post-oCRH	Basal	Post-oCRH		
1	M	362.9	24.5	72.9	5.0	496.0	14.8 (R)	260.0 (R)	M	RE
2	L	255.3	95.2	55.9	4.6	9.8	2.7 (R)	5.5 (R)	L	PER
3	R	343.9	62.9	72.8	4.7	12.5	5.5 (R)	15.2 (R)	R	RE
4	R	91.4	160.8	33.3	4.8	29.3	3.6 (R)	1.5 (R)	R	RE
5	L	274.5	65.5	42.5	6.5	15.8	4.2 (R)	13.4 (R)	L	RE
6	N	178.5	136.5	179.5	1.0	1.2	1.3	1.3	L	RE
7	N	303.0	44.0	42.5	7.1	9.6	9.6 (R)	4.4 (R)	R	RE
8	N	42.5	388.0	46.5	8.3	5.3	9.1 (L)	4.5 (L)	L	RE
9	R	193.0	49.0	68.0	2.8	15.0	3.7 (R)	17.9 (R)	R	RE
10	R	282.0	59.0	61.0	4.6	6.5	4.8 (R)	6.1 (R)	Not done	
11	L	385.5	704.0	78.0	9.0	12.4	1.8 (L)	1.9 (L)	L	RE
12	L	643.5	87.0	57.5	11.2	17.7	7.0 (R)	2.6 (R)	M	RE
13	M	51.0	288.0	38.0	7.6	11.8	5.7 (L)	6.3 (L)	R	RE
14	R	17.5	13.5	10.0	1.8	43.7	1.3	32.8 (R)	R	PER
15	L	327.0	341.0	59.0	5.8	6.3	1.0	1.2	M	RE
16	M	475.0	76.5	52.0	9.1	10.8	10.8 (R)	9.3 (R)	R	RE
17	R & L	44.0	54.0	13.0	4.2	8.6	1.3	1.8 (L)	R & L	RE
18	N	161.5	160.0	21.5	7.5	10.7	1.0	1.3	M	PER

CT=computed tomography; MRI=magnetic resonance imaging; ACTH=adrenocorticotropic; C/P=central to peripheral; IPS=inter-inferior petrosal sinus; R=right; L=left; P=peripheral; oCRH=ovine corticotropin-releasing hormone; M=midline; RE=remission; PER=persistence; N=negative.

### BIPSS results

As shown in Figures 1 and 2, the sensitivities of BIPSS were 89% (16/18) and 94% (17/18), respectively, using C/P ratio  $\geq 2$  at baseline or  $\geq 3$  after oCRH stimulation. In patient no. 14, the C/P ratio was non-diagnostic at baseline but turned positive after stimulation. In patient no. 6, who had a recurrence and no visible tumor on imaging studies, the C/P ratio was non-diagnostic at both baseline and after oCRH stimulation.

As far as lateralization was concerned, the sensitivities of BIPSS lateralization were 53% (9/17) at baseline and 59% (10/17) after oCRH stimulation using the criterion of IPS ratio  $\geq 1.4$ , including 2 patients (patients no. 15, 18) who had a centrally located tumor and an IPS ratio  $< 1.4$ . None of the 4 patients who had undergone previous TSH were correctly lateralized by BIPSS. If these 4 patients were excluded, the sensitivities of BIPSS lateralization in the remaining patients who had not undergone pituitary surgery increased to 70% (9/17) at baseline and 77% (10/17) after oCRH stimulation.

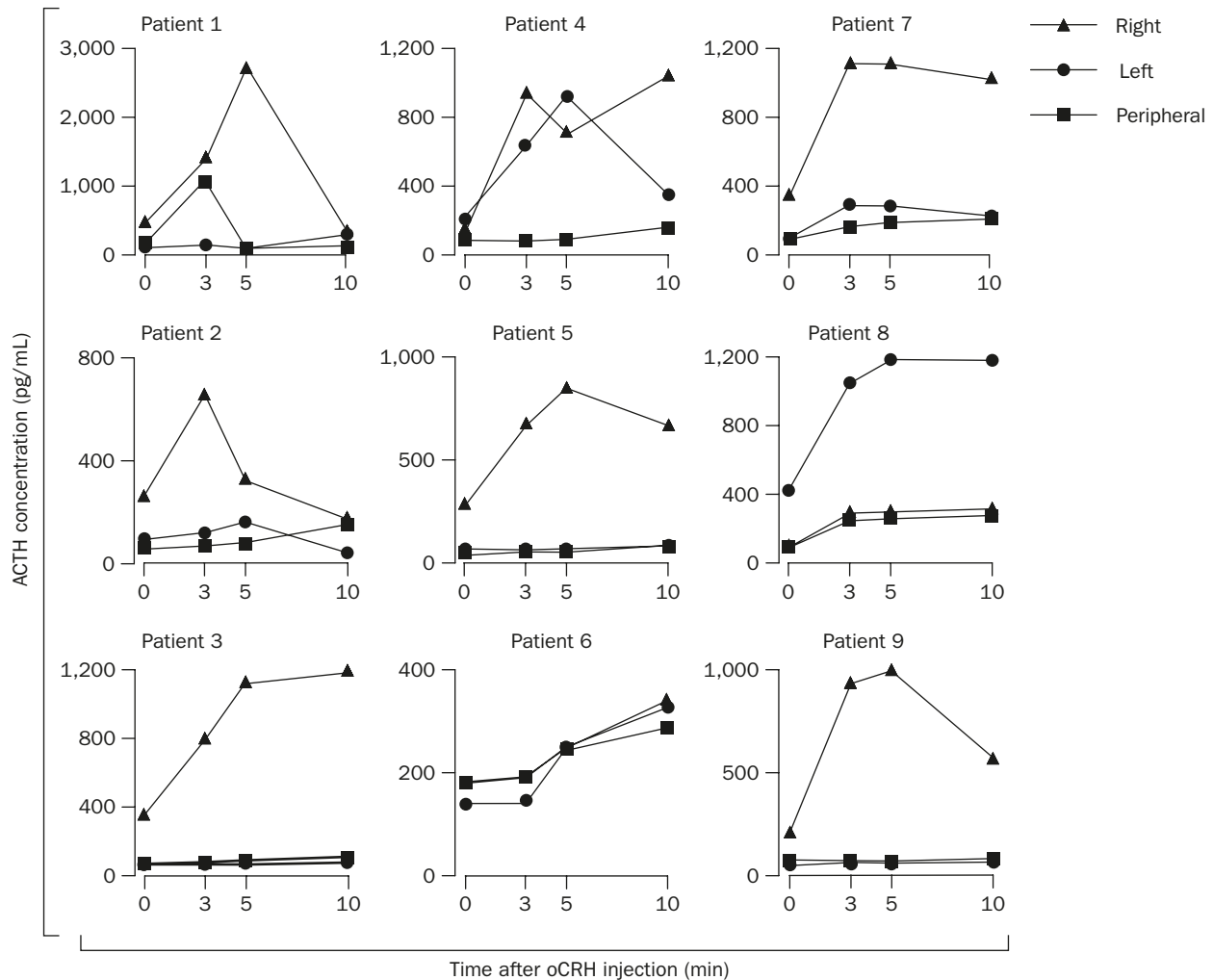
Two patients (patients no. 15, 16) were falsely lateralized by CT/MRI. Moreover, in 3 (patients no. 7, 8, 18) of the 4 patients (patients no. 6, 7, 8, 18) who had negative imaging studies, BIPSS correctly lateralized the tumor, further confirming the higher sensitivity and specificity of BIPSS.

### Efficacy and safety of BIPSS

BIPSS was successfully performed in all cases, and the sampling sites were confirmed by angiography. Patients experienced transient headache, nausea, ear discomfort and minor bruising at the puncture site, but there were no major complications.

### Discussion

CD is by far the most common cause of ACTH-dependent CS. During the past 15 years, only 1 patient suspected to have ectopic CS was encountered in our institution. A female preponderance as found in our cases is consistent with previous observations.<sup>7</sup> All of the 18 patients evaluated in this study were diagnosed with ACTH-dependent CS based on biochemical evidence of hypercortisolism (loss of circadian rhythm of serum cortisol, elevated 24-hour UFC excretion and/or non-suppressible serum cortisol in LDDST) associated with normal or high plasma ACTH levels. Despite the relatively low ACTH concentration in patient no. 1, a pathologically proven case of CD, recurrence was confirmed by LDDST. The sensitivities of UFC and midnight serum cortisol in the diagnosis of active CS in our series were 83% and 100%, respectively, which were



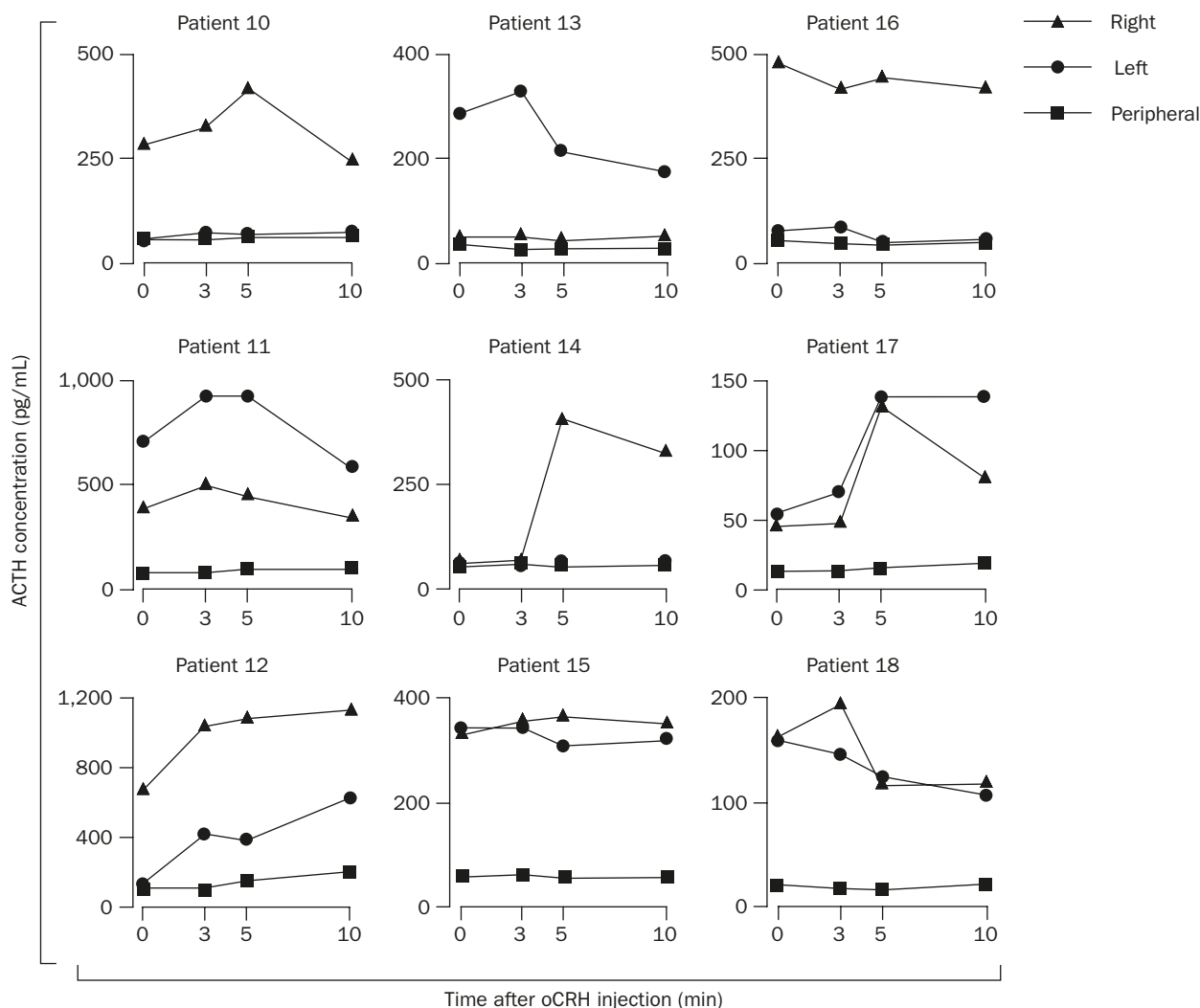
**Figure 1.** Responses of plasma adrenocorticotropin (ACTH) to ovine corticotropin-releasing hormone (oCRH) stimulation in the right and left inferior petrosal sinuses and peripheral vein in patients no. 1 to 9.

compatible with those of previous studies (71% and 96%).<sup>8,9</sup> Although only 9 patients had received LDDST, all of them, including 3 patients who had normal UFC excretion, demonstrated nonsuppressible serum cortisol level. It appears that, in our series, midnight serum cortisol and LDDST had higher sensitivities than UFC in the diagnosis of CS.

Among the noninvasive tests for differentiating CD from ectopic CS, the sensitivities of HDDST and oCRH stimulation were 69% and 71%, respectively. In our previous study, the sensitivities were 67% and 90% for HDDST and oCRH, respectively.<sup>10</sup> The lower sensitivity of the oCRH test in this series might be related to selection bias and small sample size. Imaging studies, such as CT/MRI, help to differentiate ACTH-dependent CS by detecting pituitary tumor in patients with CD, with a sensitivity ranging from 35% to 75%.<sup>11-13</sup> In our series, 14 of 18 patients were found to have a microadenoma, giving a sensitivity of 78%.

However, the results of CT/MRI may be misleading for the correct localization of tumor, as shown in this study, and the fact that pituitary incidentaloma can be found in nearly 10% of the general population.<sup>14</sup> Our results suggested, consistent with previous series, that BIPSS plus oCRH stimulation provides a more precise method for diagnosing CD patients, with superior sensitivities of 89% and 94%, before and after oCRH stimulation, respectively.<sup>15-20</sup>

Most patients with CD harbor a microadenoma that is confined to 1 side of the pituitary gland and which has venous drainage directly into the ipsilateral inferior petrosal sinus.<sup>6,21</sup> BIPSS has been widely used for preoperative assessment and for predicting lateralization, with a sensitivity ranging from 57% to 62%.<sup>20,22,23</sup> Although not as accurate as Oldfield et al's series, we found that the sensitivities of lateralization of BIPSS were 53% at baseline and 59% after oCRH stimulation. Notably, in 4 patients who had undergone



**Figure 2.** Responses of plasma adrenocorticotropic (ACTH) to ovine corticotropin-releasing hormone (oCRH) stimulation in the right and left inferior petrosal sinuses and peripheral vein in patients no. 10 to 18.

previous TSH, none were correctly lateralized by BIPSS, a finding that was similar to the observation of Vignati et al.<sup>24</sup> Altered venous drainage after surgical intervention probably contributed to the unreliable BIPSS results in those patients. Therefore, the BIPSS results in such patients may be misleading and should not be recommended. Nevertheless, BIPSS combined with oCRH stimulation correctly lateralized the tumor in 9 of the 13 and in 10 of the 13 unoperated on CD patients at baseline and after oCRH stimulation, respectively, including 3 patients who had no visible tumor on CT/MRI. Therefore, as an attempt to provide additional preoperative information for neurosurgeons, BIPSS plus oCRH stimulation appear to be a reasonable approach, especially in patients who have negative results on imaging studies. When BIPSS and CT/MRI were combined, correct lateralization was found in 12 out of 17 cases (71%).

Being highly invasive, BIPSS requires an experienced radiology team to minimize the possible risks. Nausea, headache, transient ear discomfort and groin hematomas have been occasionally reported, but major complications such as subarachnoid hemorrhage or pontine infarction are rarely encountered.<sup>23,25</sup> Successful catheterization rates described in the literature range from 65% to 100%.<sup>13,15,16,26,27</sup> Based on our limited experience, we believe that BIPSS is a safe and well-established procedure in our institution.

Limitations do exist in this study because of the small sample size and there being no available data from ectopic CS. There was also inevitable selection bias for this invasive procedure that was only performed when other tests proved to be inconclusive, rather than as routine screening at the beginning of the study, leading to difficulty in precise estimation of specificity, positive predictive value or other characteristics of test accuracy.

Larger series including more patients with CD and patients with ectopic CS are necessary to obtain further information.

In summary, we confirm that BIPSS combined with oCRH stimulation is a safe and reliable procedure not only in the differential diagnosis of ACTH-dependent CS but also in the preoperative lateralization of ACTH-secreting microadenoma in patients with CD who have not undergone previous pituitary surgery.

## References

1. Freda PU, Wardlaw SL. Diagnosis and treatment of pituitary tumors. *J Clin Endocrinol Metab* 1999;84:3859–66.
2. Newell-Price J, Trainer PJ, Besser M, Grossman A. The diagnosis and differential diagnosis of Cushing's syndrome and pseudo-Cushing's state. *Endocr Rev* 1998;19:647–72.
3. Tabarin A, Greselle JF, San-Galli F, Leprat F, Caille JM, Latapie JL, Guerin J, et al. Usefulness of the corticotropin-releasing hormone test during bilateral inferior petrosal sinus sampling for the diagnosis of Cushing's disease. *J Clin Endocrinol Metab* 1991;73:53–9.
4. Tyrrell JB, Brooks RM, Fitzgerald PA, Cofoid PB, Forsham PH, Wilson CB. Selective transsphenoidal resection of pituitary microadenomas. *N Engl J Med* 1978;298:753–8.
5. Kaye TB, Crapo L. The Cushing's syndrome: an update on diagnostic tests. *Ann Intern Med* 1990;112:434–44.
6. Oldfield EH, Chrousos GP, Schulte HM, Schaaf M, McKeever PE, Krudy AG, Culter Jr GB, et al. Preoperative lateralization of ACTH-secreting pituitary microadenomas by bilateral and simultaneous inferior petrosal sinus sampling. *N Engl J Med* 1985;312:100–3.
7. Giraldo FP, Moro M, Cavagnini F. Gender-related differences in the presentation and course of Cushing's disease. *J Clin Endocrinol Metab* 2003;88:1554–8.
8. Papanicolaou DA, Yanovski JA, Culter GB Jr, Chrousos GP, Nieman LK. A single midnight serum cortisol measurement distinguishes Cushing's syndrome from pseudo-Cushing states. *J Clin Endocrinol Metab* 1998;83:1163–7.
9. Gorges R, Knappe G, Gerl H, Ventz M, Stahl F. Diagnosis of Cushing's syndrome: re-evaluation of midnight plasma cortisol vs. urinary free cortisol and low-dose dexamethasone suppression test in a large patient group. *J Endocrinol Invest* 1999;22:241–9.
10. Lee TI, Lin SY, Won JG, Tang KT, Jap TS, Kwok CF, Lin HD. A reappraisal of the ovine corticotropin-releasing hormone test in the differential diagnosis of Cushing's syndrome: a comparison with the standard high-dose dexamethasone suppression test. *J Chin Med Assoc* 2002;65:474–82.
11. Findling JW, Raff H. Diagnosis and differential diagnosis of Cushing's syndrome. *Endocrinol Metab Clin North Am* 2001;30:729–47.
12. Colombo N, Loli P, Vignati F, Scialfa G. MR of corticotropin-secreting pituitary microadenomas. *Am J Neuroradiol* 1994;15:1591–5.
13. de Herder WW, Uitterlinden P, Pieterman H, Tanghe HL, Kwekkeboom DJ, Pols HA, Singh R, et al. Pituitary tumour localization in patients with Cushing's disease by magnetic resonance imaging: is there a place for petrosal sinus sampling? *Clin Endocrinol (Oxf)* 1994;40:87–92.
14. Hall WA, Luciano MG, Doppman JL, Patronas NJ, Oldfield EH. Pituitary magnetic resonance imaging in normal human volunteers: occult adenoma in the general population. *Ann Intern Med* 1994;120:817–20.
15. Oldfield EH, Doppman JL, Nieman LK, Chrousos GP, Miller DL, Katz DA, Cutler GB, et al. Petrosal sinus sampling with and without corticotropin-releasing hormone for the differential diagnosis of Cushing's syndrome. *N Engl J Med* 1991;325:897–905.
16. Kaltsas GA, Giannulis MG, Newell-Price JD, Dacie JE, Thakkar C, Afshar F, Monson JP, et al. A critical analysis of the value of simultaneous inferior petrosal sinus sampling in Cushing's disease and the occult ectopic adrenocorticotropic syndrome. *J Clin Endocrinol Metab* 1999;84:487–92.
17. Bonelli FS, Huston J, Carpenter PC, Erickson D, Young WFJ, Meyer FB. Adrenocorticotropic hormone-dependent Cushing's syndrome: sensitivity and specificity of inferior petrosal sinus sampling. *Am J Neuroradiol* 2000;21:690–6.
18. Colao A, Faggiano A, Pivonello R, Giraldo FP, Cavagnini F, Lombardi G. Inferior petrosal sinus sampling in the differential diagnosis of Cushing's syndrome: results of an Italian multicenter study. *Eur J Endocrinol* 2001;144:499–507.
19. Swearingen B, Katznelson L, Miller K, Grinspoon S, Waltman A, Dorer DJ, Klibanski A, et al. Diagnostic errors after inferior petrosal sinus sampling. *J Clin Endocrinol Metab* 2004;89:3752–63.
20. Liu C, Lo JC, Dowd CF, Wilson CB, Kunwar S, Aron DC, Tyrrell JB. Cavernous and inferior petrosal sinus sampling in the evaluation of ACTH-dependent Cushing's syndrome. *Clin Endocrinol* 2004;61:478–86.
21. Mampalam TJ, Wilson C. Transsphenoidal microsurgery for Cushing's disease: a report of 216 cases. *Ann Intern Med* 1988;109:487–93.
22. Lefournier V, Martinie M, Vasdev A, Bessou P, Passagia JG, Labat-Moleur F, Sturm N, et al. Accuracy of bilateral inferior petrosal or cavernous sinuses sampling in predicting the lateralization of Cushing's disease pituitary microadenoma: influence of catheter position and anatomy of venous drainage. *J Clin Endocrinol Metab* 2003;88:196–203.
23. Lopez J, Barcelo B, Lucas T, Salame F, Alameda C, Boronat M, Salto L, et al. Petrosal sinus sampling for diagnosis of Cushing's disease: evidence of false negative results. *Clin Endocrinol* 1996;45:146–56.
24. Vignati F, Berselli ME, Scialfa G, Boccardi E, Loli P. Bilateral and simultaneous venous sampling of inferior petrosal sinuses for ACTH and PRL determination: preoperative localization of ACTH-secreting microadenomas. *J Endocrinol Invest* 1989;12:235–8.
25. Miller DL, Doppman JL, Peterman SB, Nieman LK, Oldfield EH, Chang R. Neurologic complications of petrosal sinus sampling. *Radiology* 1992;185:527–8.
26. Wiggam MI, Heaney AP, McIlrath EM, McCance DR, Sheridan B, Hadden DR, Atkinson AB. Bilateral inferior petrosal sinus sampling in the differential diagnosis of adrenocorticotropic-dependent Cushing's syndrome. *J Clin Endocrinol Metab* 2000;85:1525–32.
27. Invitti C, Giraldo FP, de Martin M, Cavagnini F. Diagnosis and management of Cushing's syndrome: results of an Italian multicenter study. *J Clin Endocrinol Metab* 1999;84:440–8.